



CANM
ACMN

The Canadian Association
of Nuclear Medicine
Association canadienne
de médecine nucléaire

CANM GUIDELINES FOR IMAGING OF THE DOPAMINE TRANSPORT SYSTEM IN EVALUATION OF MOVEMENT DISORDERS

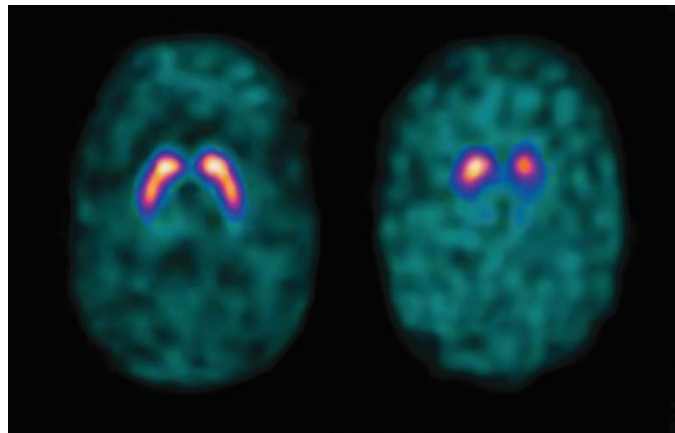


Photo credit GE Healthcare

Document prepared by

Drs. Alfonso Fasano, Ruban Gnanakumar, Heather Rigby, Andrew Ross, Jean-Paul Soucy, Alex Tamm

January 2020

ABSTRACT

In the investigation of movement disorders in which Dopamine transporter loss is a potential component, most commonly Parkinsonism, and when there is diagnostic uncertainty, imaging with 123I-ioflupane can provide important information. It is recommended in the following situations:

- 1) history or examination features that could be compatible with essential tremor (i.e. PD vs. ET)
- 2) mild or subtle signs of parkinsonism (i.e. PD vs. normal variant)
- 3) a history of prolonged exposure to a dopamine receptor blocking agent (i.e. PD vs. drug-induced parkinsonism)
- 4) distractible or variable features on exam (ie. PD vs. functional parkinsonism)
- 5) prominent dystonia (i.e. PD vs. dystonic tremor)
- 6) suspected superimposed parkinsonism (e.g. facial bradykinesia) in persons with a known neurologic disease affecting the motor system (myelopathy, stroke, neuromuscular disease, etc.)
- 7) other atypical signs (poor response to levodopa, lack of disease progression, very young onset, etc.)

The only contraindications include:

Absolute:

1. Pregnancy.
2. Inability to cooperate with brain imaging.
3. Known hypersensitivity to the active substance or to any of its excipients. An iodine allergy is not an absolute contraindication.

Relative:

1. Breastfeeding.

Patient preparation, obtaining history and ensuring the patient is not on interfering agents is vital. Additionally, exam acquisition parameters and patient positioning are an integral component to obtaining a diagnostic exam and should be followed.

The report should provide an overall impression of scan as Normal or Abnormal.

Interpretation can involve both qualitative assessment and semiquantitative analyses by physicians trained to assess the images.

The referring clinician can then utilize the results of the 123I-ioflupane scan to best manage the patient's condition.

RÉSUMÉ

Dans l'investigation des troubles du mouvement dans lesquels la perte de transporteurs de dopamine est une composante potentielle, le plus souvent dans le Parkinsonisme, en cas d'incertitude, l'imagerie à

l'iode-123 IOFLUPANE peut apporter des informations importantes. Cette investigation en médecine nucléaire est recommandée dans les situations suivantes :

- 1) Antécédents qui pourraient être compatibles avec des tremblements essentiels (Parkinsonisme versus tremblement essentiel).
- 2) Signes légers ou subtils de Parkinsonisme (Parkinsonisme versus variante de la normale).
- 3) Antécédents d'exposition prolongée à un agent bloquant les récepteurs de la dopamine (Parkinsonisme versus induction médicamenteuse).
- 4) Manifestations inhabituelles ou variables à l'examen (Parkinsonisme versus parkinsonisme fonctionnel).
- 5) Dystonie prédominante (Parkinsonisme versus tremblements dystoniques).
- 6) Suspicion de Parkinsonisme superposé (par exemple bradycardie faciale) chez des personnes connues comme porteuses de maladie neurologique affectant le système moteur (myélopathie, accident vasculo-cérébral, maladie neuromusculaire, etc.).
- 7) Autres manifestations atypiques (mauvaise réponse à la Lévodopa, absence de progression de la maladie, apparition en très jeune âge, etc.).

LES SEULES CONTRE-INDICATIONS INCLUENT :

1. Grossesse.
2. Incapacité à coopérer avec l'examen d'imagerie cérébrale.
3. Hypersensibilité connue à la substance active ou à l'un des ses éléments. Une allergie à l'iode n'est pas une contre-indication absolue.

CONTRE-INDICATION RELATIVE:

1. L'allaitement maternel

Lors de la préparation du patient, l'obtention des antécédents et de s'assurer que le patient ne prend pas d'agents perturbateurs sont de première importance.

De plus, une sélection adéquate des paramètres d'acquisition de l'examen et le positionnement du patient sont des éléments essentiels pour l'obtention d'un examen diagnostique valable.

Le rapport final doit fournir une impression globale d'une scintigraphie Normale ou Anormale.

L'interprétation peut inclure à la fois une évaluation qualitative et des analyses semi-quantitatives par les médecins formés pour interpréter ces scintigraphies.

Le médecin référent peut alors utiliser les résultats de la scintigraphie à l'iode-123 IOFLUPANE pour gérer au mieux la condition du patient.

CANADIAN ASSOCIATION OF NUCLEAR MEDICINE GUIDELINES FOR IMAGING OF THE DOPAMINE TRANSPORT SYSTEM IN EVALUATION OF MOVEMENT DISORDERS

INTRODUCTION

The Canadian Association of Nuclear Medicine (CANM) strives for excellence in the practice of diagnostic and therapeutic nuclear medicine by promoting the continued professional competence of nuclear medicine specialists, establishing guidelines of clinical practice, and encouraging biomedical research. We work with all professionals in nuclear medicine to ensure that Canadians have access to the highest quality nuclear medicine services.

These practice guidelines have been developed with input from clinician experts in movement disorders as well as neuroimaging through a consensus process and have been extensively reviewed and approved by the CANM Board of Directors. They are proposed as a reference tool to clinicians dealing with patients with movement disorders to help provide appropriate care. They are not considered to be inflexible rules or requirements of practice. The final decision regarding the ordering and use of any procedure or course of action is made by the clinician based on the situation and the clinician's judgement. These guidelines are intended for clinicians as well as nuclear medicine physicians to aid in understanding the test, provide guidance with appropriate ordering as well as for interpretation and reporting.

Clinical diagnosis of Parkinsonism is straightforward and arrived at based on clinical observations without the use of additional tests in the vast majority of cases. However, for incomplete syndromes, or an overlap between multiple concurrent conditions especially in early stage presentation, utilizing imaging of the dopamine transport system provides an improvement in diagnostic accuracy.^{1,2,3}

N-v-fluoropropyl-2b-carbomethoxy-3b-(4-123I-iodo-phenyl) nortropane (123I-ioflupane) is a molecular imaging agent used to demonstrate the location and concentration of cell membrane dopamine transporters (DaTs) located on axon terminals of nigral dopaminergic projection neurons. It has shown efficacy for detecting degeneration of the dopaminergic nigro-striatal pathway, allowing better separation of patients with essential tremor from those with Parkinsonian syndromes, as well as differentiating between some causes of Parkinsonism (e.g. functional/psychogenic or iatrogenic forms).

This document provides information and guidance for the indications, technical aspects, interpretation, and reporting of DaT single photon emissions computed tomography (SPECT) scans with 123I-ioflupane. These have been developed using the previous work of the European Association of Nuclear Medicine and the Society of Nuclear Medicine and Molecular Imaging.^{4,5,6}

INDICATIONS

Making a diagnosis of idiopathic Parkinson's disease (PD) generally relies on the identification of cardinal motor signs and the absence of features indicative of another disease with the support of levodopa responsiveness. In the vast majority of cases, the diagnosis of PD can be made based entirely on the clinical assessment. Up until 2015, the most widely accepted clinical criteria for PD diagnosis was the UK Brain bank criteria.⁶ In 2015, the International Parkinson and Movement Disorder Society published new guidelines that have been implemented in the 2nd edition of the Canadian Guideline for PD.^{7,8}

The clinical observations useful in the diagnosis of PD can however be inaccurate even in the hands of experienced neurologists, particularly early in the course of the disease. Large clinicopathological series estimate that 10-25% of patients with a clinical diagnosis of established PD will have an alternative diagnosis at autopsy.^{6,9,10,11} This underscores the important role of ancillary tests in the diagnostic work-up of select patients with Parkinsonism.

In cases of diagnostic uncertainty, DaT scanning can be considered as an aid to the clinical diagnosis³. Abnormal uptake of [123I]-FP-CIT has consistently been shown across studies to have extremely high sensitivity and specificity in cases of neurodegenerative parkinsonism associated with loss of nigrostriatal dopamine neurons.^{12,13,14,15,16,17} Clinical follow-up is the reference standard in most of these studies but is only a surrogate of the gold standard, which is the autopsy-proven definitive diagnosis. However, DaT imaging has been shown to be very accurate in the early prediction of the final clinical diagnosis obtained after long term follow-up. Importantly, DaT scanning is not helpful in differentiating between neurodegenerative parkinsonian disorders.^{17b,17c}

DaT scanning has been shown to have a substantial impact on management and confidence of diagnosis in select patients (Table 1). Indications for testing may include:^{3,5,18,19}

- 1) history or examination features that could be compatible with essential tremor (i.e. PD vs. ET)
- 2) mild or subtle signs of parkinsonism (i.e. PD vs. normal variant)
- 3) a history of prolonged exposure to a dopamine receptor blocking agent (i.e. PD vs. drug-induced parkinsonism)
- 4) distractible or variable features on exam (ie. PD vs. functional parkinsonism)
- 5) prominent dystonia (i.e. PD vs. dystonic tremor)
- 6) suspected superimposed parkinsonism (e.g. facial bradykinesia) in persons with a known neurologic disease affecting the motor system (myelopathy, stroke, neuromuscular disease, etc.)
- 7) other atypical signs (poor response to levodopa, lack of disease progression, very young onset, etc.)

Of note, there does not appear to be a diagnostic benefit to repeat scanning after a period of time if the initial scan is normal.²⁰

Table 1: Principal conditions associated with an abnormal or normal striatal uptake.

Abnormal striatal uptake of [123I]-FP-CIT	Normal striatal uptake of [123I]-FP-CIT
Parkinson's disease	Essential Tremor
Progressive Supranuclear Palsy	Dystonic Tremor
Multiple System Atrophy type P*	Drug-induced parkinsonism**
Dementia with Lewy Bodies	Functional parkinsonism
Structural lesions of the nigro-striatal system (e.g. midbrain stroke)	Dopa-responsive dystonia
DAT deficiency syndrome	

*:accuracy still unclear in MSA type C (cerebellar) **: large series have found some patients with abnormal uptake, whose condition is still unclear²¹

Variable findings

DaT imaging is a reliable surrogate of nigro-striatal degeneration and some conditions (PD in particular) are always associated with it, thus explaining the diagnostic role of SPECT scans with ¹²³I-ioflupane. In some condition however, the impairment of the nigro-striatal fiber is variable and so is the striatal uptake.

'**Vascular parkinsonism**' has undergone a drastic nosologic revision in recent years and it is now acknowledged that it is often an overdiagnosed condition in patients with degenerative diseases also featuring vascular changes of the white matter (the so-called "pseudovascular parkinsonism").²² In some cases of pseudovascular parkinsonism a more diffuse and symmetrical reduction of uptake is observed²³ often with irregularities in the profile of the putamen. In "definite" vascular parkinsonism there is an ischemic or hemorrhagic stroke involving the substantia nigra and/or nigrostriatal pathway and DaT imaging is positive. Most of these cases are unilateral parkinsonism. By contrast, DaT is normal in "vascular pseudoparkinsonism" (e.g., akinetic mutism resulting from bilateral mesial frontal strokes or apathetic depression from bilateral striatal lacunar strokes).²⁴

Cortico-basal syndrome (CBS) is the most challenging movement disorder from a diagnostic standpoint as its underlying pathology is cortico-basal degeneration only in a minority of cases (other being caused by progressive supranuclear palsy (PSP), Alzheimer or even prion pathology). Not surprisingly DaT imaging is variable depending on the underlying pathology, with some cases showing normal uptake.²⁵

A similar scenario is seen in **orthostatic tremor** (OT), in which an abnormal DaT is supposed to be found in the so-called 'plus' forms (as opposed to primary or secondary forms), occurring when OT is associated with PD or other cases of degenerative parkinsonism.²⁶

Likewise, **primary progressive freezing of gait** may herald many different degenerative processes and an abnormal DaT is seen in cases caused by PSP pathology while a normal uptake is more often seen in cases evolving towards CBS or motor neuron diseases.²⁷

Holmes tremor is another heterogenous condition supposedly caused by a strategic (usually vascular) lesion involving both the nigro-striatal system and the cerebello-thalamic fibers. However, due to the variability of lesions, a normal DaT study is still possible (e.g. in case of lesions not involving the midbrain).²⁸

Many other conditions are associated with variable involvement of the nigra which therefore present with different DaT imaging appearances (e.g. Huntington disease) and in some cases an improvement of the uptake has been reported following treatment, such as in Normal Pressure Hydrocephalus (NPH). Not many papers have explored the role of DaT imaging in NPH but the following scenarios can be hypothesized: 1) an abnormal uptake in patients with co-existing PD or other degenerative conditions involving the pars compacta of the substantia nigra, 2) an abnormal uptake in patients mistakenly diagnosed with NPH while having PD or other degenerative conditions involving the pars compacta of the substantia nigra, 3) a normal uptake (e.g. in the so-called "pseudovascular pseudoparkinsonism"²⁹, and 4) an abnormal uptake caused by the mechanical compression of the fiber reaching the putamen.

The role of DaT imaging in research

DaT imaging has different roles in research protocols, some of which is still not fully explored but at least 5 principal applications can be listed here:

1. DaT imaging as a biomarker to assess PD progression, for example, in the Parkinson Progression Marker Initiative funded by the Michael J Fox Foundation³⁰
2. Study of the regional differences in uptake to understand different PD presentations
3. Use of DaT imaging as endophenotype in populations at risk of developing PD, such as carriers of genetic mutation³¹ or patients with REM sleep behavioral disorder
4. DaT scanning can be used as a marker of the protective effect of surgical³² or pharmacological treatment.³³

As for the last point, it should be emphasized that the DaT expression is influenced by factors other than number of dopaminergic neurons (e.g. up or downregulation influenced by drugs), thus its role in proving a disease modifying effect is object of debate.

CONTRAINDICATIONS

Absolute:

1. Pregnancy.
2. Inability to cooperate with brain imaging.
3. Known hypersensitivity to the active substance or to any of its excipients. An iodine allergy is, however, not an absolute contraindication to receiving this radiotracer.

Relative:

Breastfeeding. If possible, consider delaying the examination until breastfeeding has ceased. It is unknown if ioflupane is secreted in human milk, therefore, if administration is considered necessary, breast-feeding should be interrupted for a minimum of 1 day and up to 6 days.^{34,35,36}

REQUEST/REQUISITION SUGGESTED FORMAT

The suggested format for the requisition is to have boxes to allow the referring clinician to provide the following information:

- a. Description of patient symptoms and clinical question
 - For neurological symptoms, specify the type, duration, and right or left sidedness
- b. Relevant past medical history
 - This would include history of brain surgery, trauma or tumor, stroke, psychiatric illness and epilepsy
- c. List of current medications
 - For any medications that may affect tracer binding (see below), indicate when the medication was last taken
- d. History of use of recreational drugs that affect tracer binding (see below)
 - If so, indicate when it was last taken
- e. Previous brain imaging studies, including date and location of study
 - This should include CT, MRI, SPECT, PET
- f. Can the patient lie still for 30-45 minutes for the test?

PATIENT PREPARATION

Prior to arrival, medications that may alter tracer binding should be stopped, if possible, for at least 5 half-lives (see Table 2 for medications, durations to be held, and effect on imaging). The decision to withdraw medications should be made by the specialist caring for the patient after weighing benefits and risks.

Table 2

Drug/condition	Effect on Striatal Binding	Evidence	Recommended duration to hold (Half-Life)
Cocaine	↓	H ³⁷	2 days ^{37b} (1 hr)
Amphetamines	↓	A ³⁸ , H ^{39,40}	3-7 days ^{37b} (5-30 hrs)
CNS Stimulants	↓	T	
Phentermine			6 d (25hrs)
Ephedrines			30 hrs (6hrs)
Modafinil	↓	A ⁴¹	3 d ^{37b} (15 hrs)
Antidepressants			
Mazindol	↓	H ⁴²	3 days ^{37b} (10-13hrs)
Bupropion	↔ or ↓	H ^{43,44,45,46}	8 days ^{37b} (12-30hrs)
Radafaxine (NDRI)	↓	H ⁴⁷	
SSRIs	↑ but no effect on visual assessment	H ^{46,48,49,50}	Not required
SNRIs	↑ but no effect on visual assessment	H ⁵¹	Not required
Tricyclic Antidepressants	↔	A ⁵⁰	Not required
Adrenergic Agonists (Phenylephrine, norepinephrine)	↑ when infused at high doses		
Anticholinergics			
Benzatropine	↓	A ⁵²	5 days ^{37b} (12-24 hrs)
Others like scopolamine	↑ but no effect on visual assessment	A ⁵³	2 days (9.5 hrs)
Opioids			
Fentanyl	↓	A ^{54,55}	20 hrs (2-4hrs)
Naltrexone	↔	CR ⁵⁶ H ⁵⁷	Not required
Anesthetics	↓	A ^{58,59}	
Ketamine		H ⁶⁰	15 hrs (3 hrs)
Phencyclidine			10 days (7-46 hrs)
Isoflurane			10.5min (2.1min)
Antiparkinsonian medications	↔, although caution is advised in intraindividual follow-up studies (possible DAT downregulation with L-DOPA)		

L-DOPA ⁶⁰		H ^{61,62}	Not required
Dopamine agonists		H ^{63,64}	Not required
NMDA receptor blockers		T	Not required
MAO-B inhibitors		H ^{65,66}	Not required
COMT inhibitors		T	Not required
Cholinesterase Inhibitors	↔	H ⁶⁷	Not required
Neuroleptics/Antipsychotics	↔	A ⁶⁸ , H ⁶⁹	Not required
Estrogen replacement post menopause	↑ but no effect on visual assessment	H ⁷⁰	Not required
Menstrual cycle	↔		
Lithium	↓	CR ⁷¹	5 days (24 hrs)

↑ = increase binding, ↓ = decrease binding, ↔ = no effect, NDRI = norepinephrine-dopamine reuptake inhibitor, SSRI = selective serotonin reuptake inhibitors, SNRIs = Serotonin-norepinephrine reuptake inhibitors, MAO-B = monoamine oxidase-B, COMT = catechol-O-methyltransferase, DAT = dopamine transporter. T = theoretical, H = human data, A = animal data., CR = case report

At least 1 hour prior to radiotracer injection, a single 400mg dose of potassium perchlorate or 100mg equivalent of iodide in Lugol's solution should be administered to reduce exposure of the thyroid to free ¹²³I. This is not mandatory as the radiation dose expected to the thyroid gland would be very low and it may be avoided if patients are known to have sensitivities. A dim or quiet environment is not necessary for the uptake period.

IMAGING

Set Up and Positioning

2.5 or 5-mL solution containing 185 or 370MBq of ¹²³I-ioflupane is administered intravenously as a slow bolus over roughly 20 s followed by a saline flush. ³ Binding of the radiotracer is stable between 3 and 6 hours after injection, at which point SPECT imaging can be acquired. It is encouraged that each centre optimize reproducibility and reduce variability by maintaining the same interval. ^{56,72,73}

Voiding is recommended prior to scanning to avoid interruptions and frequently after imaging to reduce radiation exposure. All eyeglasses, earrings, hair clips, combs or hearing aids should be removed if possible.⁷⁴ The patient should be supine with the head straight (chin in neutral position and vertical canthomeatal line) and instructed to remain still during the image acquisition. Reducing head tilt is desirable but should not jeopardize patient comfort as images can be reoriented following acquisition. The corpus striatum(caudate nucleus and putamen) and occiput are required in the field of view. A case by case strategic decision should be considered in patients with L-DOPA induced dyskinesias as whether to hold the drug. Patients with severe tremor should likely be scanned under the effect of the therapy but this noted in the report. Although rarely of use, restraint devices can be utilized to minimize movement. If movement is an issue, short-acting benzodiazepine sedation does not affect image quality and can be used if agreed upon by the patient or patient's legal representative, referring physician and the patient has arranged appropriate transport following the exam.³⁵

Equipment & Image Acquisition

Detector:

Multiple detector or dedicated SPECT camera are strongly preferred over single headed cameras due to shortened scan time to achieve adequate counts at the routine doses administered for data acquisition.³⁵ The field of view should include the entire brain and the smallest possible, safe rotation radius should be used (typically 11-15cm).³⁵

Collimator:

Low Energy High Resolution (LEHR) parallel-hole collimation is adequate, but, if available, fan-beam collimators may be preferred for improved resolution at the cost of count rate capability.

Photopeak:

The photopeak should be 159keV +/- 10%. Additional energy windows can be used for scatter correction.

Matrix:

A 128 x 128 matrix is recommended. Acquisition pixel size should be one-third to one-half of the expected resolution. Hardware zoom may be necessary to achieve an appropriate pixel size of 3.5-4.5mm. Slices should be 1 pixel thick.

Angular Sampling, Scan Time and Total Detected Events:

3-degree angular sampling for 360 degrees of coverage (180 degrees for each head in a dual head camera) is recommended, although continuous rotation may also be used. The number of seconds per position depends on the sensitivity of the system, but usually 30-40s are required.

A minimum of 1.5 million total counts should be collected for optimal images if scatter correction is applied (otherwise >3 million). Total acquisition time will vary according to camera specifications, but is often between 30-45 minutes. Consider segmenting data acquisition into multiple sequential acquisitions which may permit exclusion of data with artefacts (i.e. exclude segments with movement artifact).

Image Processing:

Projection data in cine mode and sinograms should be displayed to assess scan quality of data, patient motion, and artifacts. Rescanning will be required for large movements, but motion correction can be applied to correct for minor movements.

Iterative reconstruction is preferred but filtered back projection is adequate. The entire brain volume should be reconstructed at the highest pixel resolution (i.e. one-pixel slice thickness). A low-pass filter (i.e. Butterworth) is recommended and should preserve the linearity of the count rate response. Other filters may introduce artifact and are not recommended for general use. All 3 dimensions should be filtered either by 2D prefiltering of the projection data or by applying a 3D postfilter to the reconstructed data.

Attenuation correction is recommended. Attenuation maps can be measured from a sequentially or simultaneously acquired CT or transmission scan or calculated according to the Chang technique (broad beam linear correction coefficient for ¹²³I: $\mu = 0.11\text{cm}^{-1}$). Variance may occur with fan-beam collimators and accuracy should be verified with an appropriate phantom.

Images are reconstructed into slices in 3 standard planes (axial, coronal, sagittal). Transverse slices should be parallel to a standard, reproducible anatomic orientation, such as the anterior commissure-posterior commissure line. Correct reorientation aids visual assessment and is crucial for quantitative assessments.

Quantification assesses the ratio of activity in a structure/region of interest to activity in a reference region (generally striatum or striatal subregions compared to the occipital area (or possibly cerebellum)). Regions/volumes of interest may be drawn manually, using automated systems or voxel-based mathematical systems. For both manual and automated semiquantification, the left and right striatum as well as the caudate and putamen should be quantified separately.

INTERPRETATION

In general, visual assessment of the images is sufficient to make an accurate diagnosis when the uptake is clearly abnormal. However, the addition of semiquantification has been shown to allow readers with limited experience in the interpretation of DaT imaging to perform as well as more experienced readers. The addition of semiquantification and comparison to age matched normal values has also been shown to increase reader confidence in the interpretation of DaT imaging.

The images should be viewed using appropriate computer software, which allows for adjustment of the alignment, colour table, background subtraction or contrast. It is recommended that readers become familiar with one color scale to allow for consistency in interpretation between studies.

Visual interpretation should begin by assessing the quality of the images. Alignment of the head should be checked, as a misalignment could result in artificial asymmetry and a misinterpretation of the images. The raw images of the SPECT scan should be viewed in the cine mode or sinogram mode to assess for movement or other technical artifacts. If applicable, the possible affect of any medications known to interfere with 123I-ioflupane striatal binding should be considered. Using a fixed set of reference images at all levels (Normal to severe decrease) can aid in providing a qualitative assessment of uptake.

The striata should be assessed for their shape, extent, symmetry and intensity. On axial images in a normal study the striata will be symmetric with well defined borders and have a comma or crescent shape. Abnormal studies are characterized by decreased intensity of the striatum on one or both sides, as well as decrease in size to a circle or oval shape.

The head of the caudate and the putamen should have high contrast to the background in patients of all ages and for all colour scales. With normal aging, some decrease in striatal binding occurs in both the caudate and putamen and should be recognized to avoid overinterpretation. Activity in the head of the caudate should be compared to activity in the putamen, as when abnormal, the putamen is usually more severely affected than the caudate nucleus, especially in iPD. In a normal healthy patient, the striata should be fairly symmetric although mild asymmetry may be seen. In the disease state, abnormalities usually first become visible in the putamen contralateral to the neurological signs.

Some common patterns can be seen on visual interpretation. In Parkinson's disease, there is usually a decrease in activity in the dorsal putamen contralateral to the neurological signs and this progresses anteriorly ipsilaterally over time. In contrast, in atypical Parkinson's syndromes the abnormalities tend to be more symmetric and involve more of the caudate.

In cases of vascular parkinsonism, striatal uptake is usually normal or only slightly decreased except in cases of striatal infarcts. An infarct usually appears as a punched out defect when compared to the neurodegenerative syndrome abnormalities described above.

Correlation with available CT or MRI studies of the brain should occur and may provide additional information that could aid in accurate interpretation of studies, in particular by showing anatomic lesions that may alter the appearance of the striatal structures.

QUANTITATIVE ANALYSES

Quantification with use of validated age-matched reference values may be helpful to accurately interpret DaT imaging. Further benefits of quantification include earlier detection of disease, the ability to objectively assess loss of presynaptic dopaminergic neurons over subsequent studies and providing useful data for research and multicenter studies.

There is no universally accepted cut-off value for normal or abnormal, as quantitative data can be affected by the camera system, calibration, image acquisition protocol, post-acquisition processing including corrections and quantification protocol. Quantitative data needs to be compared to a suitable database of reference values, ideally age-matched. To use quantification, each site needs to determine a reference range by scanning a population of healthy controls or alternatively calibrate its procedure with a site that has a reference database. Cross-calibration can be done by establishing the relationship between measured uptake ratio and true activity using an anthropomorphic phantom filled with different concentrations of activity and comparing to the same done at another site.

Quantification is subject to interobserver variability especially for inexperienced readers, which may be secondary to differences in reorientation of the head and errors in placement of the reference regions of interest. However, this can be overcome with the use of automated systems to analyze volumes of interest.

For manual quantification, standardized alignment of the head should be used and the sum of at least 3 consecutive slices with standardized region of interests of at least twice the full width and half maximum represents the minimum requirement of tissue volume sampling. A consistent number of slices should be used. For automated quantification, a 3D volume of interest is preferred but the placement of the region of interest should be checked visually.

Quantitative data can be reported as striatal binding expressed as percentage of normal binding for age-matched reference uptake.

REPORT

The report should include the usual demographic information used in imaging reports at the imaging site for example the patient's name, date of birth and hospital identification number. The name of the referring physician and date of the scan should also be included.

a) History

The provided clinical history should be included in the report, including the type, duration and side of neurological symptoms and any relevant past medical history.

State whether the patient is on any drugs known to interfere with ¹²³I-ioflupane binding, and if so which drugs.

If sedation was used, state the dosage, route and timing in relation to the scan.

b) Technique

State the injected dose the radiopharmaceutical, the elapsed time between the injection of the radiopharmaceutical and image acquisition.

c) Findings

Describe any factors that limit image quality, such as patient motion.

Describe the visual interpretation of striatal binding as normal or abnormal. If abnormal, report the location and severity of reduced striatal binding. For severity of reduced binding descriptions such as mild, moderate and severe are suggested. If relevant, compare the findings with any previous 123I-ioflupane studies for the patient. Correlate with previous ¹⁸F-FDG PET, CT or MRI studies of the brain, as applicable.

If semiquantitative analysis was performed, report the values and reference range. An age matched reference range is preferred.

d) Impression

State overall impression of scan as Normal or Abnormal.

An abnormal study indicates that a presynaptic striatal dopaminergic terminals deficit is present and can be seen in conditions such as PD, PSP, multiple system atrophy, and dementia with Lewy bodies. The reporting physician should avoid referring to a clear diagnosis for example, PD, as these remain a clinical diagnosis for which. DATscan provides supportive information. If required to clarify the diagnosis, further studies such as 18F-FDG PET may be recommended.

REFERENCES

¹ Meara J, Bhowmick BK, Hobson P. Accuracy of diagnosis in patients with pre-sumed Parkinson's disease. *Age Ageing*. 1999;28:99–102.

² Hughes AJ, Ben-Shlomo Y, Daniel SE, Lees AJ. What features improve the accuracy of clinical diagnosis in Parkinson's disease: a clinicopathologic study. *Neurology*. 2001;57(suppl 3):S34–S38.

³ Marshall V, Grosset D. Role of dopamine transporter imaging in routine clinical practice. *Mov Disord*. 2003;18:1415–1423.

⁴ Darcourt J, Booij J, Tatsch K, et al. EANM procedure guidelines for brain neurotransmission SPECT using 123I-labelled dopamine transporter ligands, version 2. *Eur J Nucl Med Mol Imaging*. 2010;37:443–450.

⁵ David S.W. Djang¹, Marcel J.R. Janssen², et al. SNM Practice Guideline for Dopamine Transporter Imaging with 123I-ioflupane SPECT 1.0 THE JOURNAL OF NUCLEAR MEDICINE • Vol. 53 • No. 1 • January 2012.

⁶ Hughes AJ, Daniel SE, Kilford L, Lees AJ. Accuracy of clinical diagnosis of idiopathic Parkinson's disease: a clinicopathological study of 100 cases. *J Neurol Neurosurg Psychiatry* 1992;55:181-184.

⁷ Postuma RB, Berg D, Stern M, et al. MDS clinical diagnostic criteria for Parkinson's disease. *Mov Disord* 2015;30:1591-1601.

⁸ Grimes D, Fitzpatrick M, Gordon J, et al. Canadian guideline for Parkinson disease. *CMAJ* 2019;191:E989-E1004.

⁹ Adler CH, Beach TG, Hentz JG, et al. Low clinical diagnostic accuracy of early vs advanced Parkinson disease: Clinicopathologic study. *Neurology* 2014;83:406-412.

¹⁰ Hughes AJ, Daniel SE, Lees AJ. Improved accuracy of clinical diagnosis of Lewy body Parkinson's disease. *Neurology* 2001;57:1497-1499.

¹¹ Jellinger KA. The neuropathologic diagnosis of secondary parkinsonian syndromes. *Adv Neurol* 1996;69:293-303.

¹² Benamer TS, Patterson J, Grosset DG, et al. Accurate differentiation of parkinsonism and essential tremor using visual assessment of [123I]-FP-CIT SPECT imaging: the [123I]-FP-CIT study group. *Mov Disord* 2000;15:503-510.

-
- ¹³ Catafau AM, Tolosa E. Impact of dopamine transporter SPECT using 123I-IOFLUPANE on diagnosis and management of patients with clinically uncertain Parkinsonian syndromes. *Mov Disord* 2004;19:1175-1182.
- ¹⁴ Marshall VL, Reiningner CB, Marquardt M, et al. Parkinson's disease is overdiagnosed clinically at baseline in diagnostically uncertain cases: a 3-year European multicenter study with repeat [123I]FP-CIT SPECT. *Mov Disord* 2009;24:500-508.
- ¹⁵ Sadasivan S, Friedman JH. Experience with DaTscan at a tertiary referral center. *Parkinsonism Relat Disord* 2015;21:42-45.
- ¹⁶ Vlaar AM, de Nijs T, Kessels AG, et al. Diagnostic value of 123I-ioflupane and 123I-iodobenzamide SPECT scans in 248 patients with parkinsonian syndromes. *Eur Neurol* 2008;59:258-266.
- ^{17a} Pirker W, Asenbaum S, Bencsits G, et al. [123I]beta-CIT SPECT in multiple system atrophy, progressive supranuclear palsy, and corticobasal degeneration. *Mov Disord* 2000;15:1158-1167.
- ^{17b} Vlaar AM, de Nijs T, Kessels AG, et al. Diagnostic value of 123I-ioflupane and 123I-iodobenzamide SPECT scans in 248 patients with parkinsonian syndromes. *Eur Neurol* 2008;59:258-266.
- ^{17c} Pirker W, Asenbaum S, Bencsits G, et al. [123I]beta-CIT SPECT in multiple system atrophy, progressive supranuclear palsy, and corticobasal degeneration. *Mov Disord* 2000;15:1158-1167.
- ¹⁸ Bega D, Gonzalez-Latapi P, Zadikoff C, Spies W, Simuni T. Is There a Role for DAT-SPECT Imaging in a Specialty Movement Disorders Practice? *Neurodegener Dis* 2015;15:81-86.
- ¹⁹ Kupsch AR, Bajaj N, Weiland F, et al. Impact of DaTscan SPECT imaging on clinical management, diagnosis, confidence of diagnosis, quality of life, health resource use and safety in patients with clinically uncertain parkinsonian syndromes: a prospective 1-year follow-up of an open-label controlled study. *J Neurol Neurosurg Psychiatry* 2012;83:620-628.
- ²⁰ Apostolova I, Taleb DS, Lipp A, et al. Utility of Follow-up Dopamine Transporter SPECT With 123I-FP-CIT in the Diagnostic Workup of Patients With Clinically Uncertain Parkinsonian Syndrome. *Clin Nucl Med* 2017;42:589-594.
- ²¹ Tinazzi M, Morgante F, Matinella A, Bovi T, Cannas A, Solla P, Marrosu F, Nicoletti A, Zappia M, Luca A, Di Stefano A, Morgante L, Pacchetti C, Minafra B, Sciarretta M, Dallochio C, Rossi S, Ulivelli M, Ceravolo R, Frosini D, Cipriani A, Barbui C. Imaging of the dopamine transporter predicts pattern of disease progression and response to levodopa in patients with schizophrenia and parkinsonism: a 2-year follow-up multicenter study. *Schizophr Res*. 2014 Feb;152(2-3):344-9. doi: 10.1016/j.schres.2013.11.028. Epub 2013 Dec 25. PubMed PMID: 24369987.
- ²² Vizcarra JA, Lang AE, Sethi KD, Espay AJ. Vascular Parkinsonism: deconstructing a syndrome. *Mov Disord*. 2015 Jun;30(7):886-94. doi: 10.1002/mds.26263. Epub 2015 May 21.
- ²³ Cummings et al. *Brain* 2011.
- ²⁴ Vizcarra JA, Lang AE, Sethi KD, Espay AJ. Vascular Parkinsonism: deconstructing a syndrome. *Mov Disord*. 2015 Jun;30(7):886-94. doi:10.1002/mds.26263. Epub 2015 May 21.
- ²⁵ Cilia R, Rossi C, Frosini D, Volterrani D, Siri C, Pagni C, Benti R, Pezzoli G, Bonuccelli U, Antonini A, Ceravolo R. Dopamine Transporter SPECT Imaging in Corticobasal Syndrome. *PLoS One*. 2011 May 2;6(5):e18301. doi: 10.1371/journal.pone.0018301. PubMed PMID: 21559307;
- ²⁶ Estre TA, Lang AE, Ferreira JJ, Almeida V, de Carvalho M, Miyasaki J, Chen R, Fox S. Associated movement disorders in orthostatic tremor. *J Neurol Neurosurg Psychiatry*. 2012 Jul;83(7):725-9. doi: 10.1136/jnnp-2012-302436. Epub 2012 May 10. Erratum in: *J Neurol Neurosurg Psychiatry*. 2012 Nov;83(11):1132. Lang, A E [corrected to Lang, Anthony EJ]. PubMed PMID: 22577231.
- ²⁷ Fasano A, Baldari S, Di Giuda D, Paratore R, Piano C, Bentivoglio AR, Girlanda P, Morgante F. Nigro-striatal involvement in primary progressive freezing gait: insights into a heterogeneous pathogenesis. *Parkinsonism Relat Disord*. 2012 Jun;18(5):578-84. doi: 10.1016/j.parkreldis.2012.03.002. Epub 2012 Mar 28. PubMed PMID: 22459564.
- ²⁸ Gajos A, Budrewicz S, Koszewicz M, Bieńkiewicz M, Dąbrowski J, Kuśmierk J, Sławek J, Bogucki A. Is nigrostriatal dopaminergic deficit necessary for Holmes tremor to develop? The DaTSCAN and IBZM SPECT study. *J Neural Transm (Vienna)*. 2017 Nov;124(11):1389-1393. doi: 10.1007/s00702-017-1780-1. Epub 2017 Aug 23. PubMed PMID: 28836067; PubMed Central PMCID: PMC5653710.
- ²⁹ Vizcarra JA, Lang AE, Sethi KD, Espay AJ. Vascular Parkinsonism: deconstructing a syndrome. *Mov Disord*. 2015 Jun;30(7):886-94. doi: 10.1002/mds.26263. Epub 2015 May 21.
- ³⁰ Parkinson Progression Marker Initiative. The Parkinson Progression Marker Initiative (PPMI). *Prog Neurobiol*. 2011 Dec;95(4):629-35. doi: 10.1016/j.pneurobio.2011.09.005. Epub 2011 Sep 14. Review. PubMed PMID: 21930184.

- ³¹ Ricciardi L, Petrucci S, Di Giuda D, Serra L, Spanò B, Sensi M, Ginevrino M, Cocciolillo F, Bozzali M, Valente EM, Fasano A. The Contursi Family 20 Years Later: Intrafamilial Phenotypic Variability of the SNCA p.A53T Mutation. *Mov Disord*. 2016 Feb;31(2):257-8. doi: 10.1002/mds.26549. Epub 2016 Jan 22. PubMed PMID: 26799529.
- ³² Hesse S, Strecker K, Winkler D, Luthardt J, Scherfler C, Reupert A, Oehlwein C, Barthel H, Schneider JP, Wegner F, Meyer P, Meixensberger J, Sabri O, Schwarz J. Effects of subthalamic nucleus stimulation on striatal dopaminergic transmission in patients with Parkinson's disease within one-year follow-up. *J Neurol*. 2008 Jul;255(7):1059-66. doi: 10.1007/s00415-008-0849-z. Epub 2008 May 2. PubMed PMID: 18446306.
- ³³ Morrish PK. How valid is dopamine transporter imaging as a surrogate marker in research trials in Parkinson's disease? *Mov Disord*. 2003 Oct;18 Suppl 7:S63-70. Review. PubMed PMID: 14531048.
- ³⁴ DaTscan (English) Product Monograph Canada Control No 201481 (December 7 2017).pdf.
- ³⁵ Djang, D. S. W. et al. SNM Practice Guideline for Dopamine Transporter Imaging with 123I-iodoflupane SPECT 1.0. *J. Nucl. Med.* **53**, 154–163 (2012).
- ³⁶ Darcourt, J. et al. EANM procedure guidelines for brain neurotransmission SPECT using 123I-labelled dopamine transporter ligands, version 2. *Eur. J. Nucl. Med. Mol. Imaging* **37**, 443–450 (2010).
- ³⁷ Volkow, N. D. et al. Relationship between subjective effects of cocaine and dopamine transporter occupancy. *Nature* **386**, 827–830 (1997).
- ³⁸ Laruelle, M. et al. SPECT imaging of dopamine and serotonin transporters with [123I]beta-CIT: pharmacological characterization of brain uptake in nonhuman primates. *Synap. N. Y. N* **13**, 295–309 (1993).
- ³⁹ Volkow, N. D. et al. Association of Dopamine Transporter Reduction With Psychomotor Impairment in Methamphetamine Abusers. *Am. J. Psychiatry* **158**, 377–382 (2001).
- ⁴⁰ Chou, Y.-H. et al. Dopamine transporters and cognitive function in methamphetamine abuser after a short abstinence: A SPECT study. *Eur. Neuropsychopharmacol.* **17**, 46–52 (2007).
- ⁴¹ Madras, B. K. et al. Modafinil Occupies Dopamine and Norepinephrine Transporters in Vivo and Modulates the Transporters and Trace Amine Activity in Vitro. *J. Pharmacol. Exp. Ther.* **319**, 561–569 (2006).
- ⁴² Malison, R. T. et al. [123I]-CIT SPECT imaging of dopamine transporter availability after mazindol administration in human cocaine addicts. **5**.
- ⁴³ Árgyelán, M. et al. Dopamine transporter availability in medication free and in bupropion treated depression: A 99mTc-TRODAT-1 SPECT study. *J. Affect. Disord.* **89**, 115–123 (2005).
- ⁴⁴ Meyer, J. H. et al. Bupropion occupancy of the dopamine transporter is low during clinical treatment. *Psychopharmacology (Berl.)* **163**, 102–105 (2002).
- ⁴⁵ Learned-Coughlin, S. M. et al. In vivo activity of bupropion at the human dopamine transporter as measured by positron emission tomography. *Biol. Psychiatry* **54**, 800–805 (2003).
- ⁴⁶ Kugaya, A. et al. Changes in Human In vivo Serotonin and Dopamine Transporter Availabilities during Chronic Antidepressant Administration. *Neuropsychopharmacology* **28**, 413–420 (2003).
- ⁴⁷ Volkow, N. D. et al. The slow and long-lasting blockade of dopamine transporters in human brain induced by the new antidepressant drug radafaxine predict poor reinforcing effects. *Biol. Psychiatry* **57**, 640–646 (2005).
- ⁴⁸ de Win, M. M. L. et al. Validation of [123I]β-CIT SPECT to Assess Serotonin Transporters In Vivo in Humans: a Double-Blind, Placebo-Controlled, Crossover Study with the Selective Serotonin Reuptake Inhibitor Citalopram. *Neuropsychopharmacology* **30**, 996–1005 (2005).
- ⁴⁹ Booij, J. et al. Quantification of Striatal Dopamine Transporters with 123I-FP-CIT SPECT Is Influenced by the Selective Serotonin Reuptake Inhibitor Paroxetine: A Double-Blind, Placebo-Controlled, Crossover Study in Healthy Control Subjects. *J. Nucl. Med.* **48**, 359–366 (2007).
- ⁵⁰ Booij, J. & Kemp, P. Dopamine transporter imaging with [123I]FP-CIT SPECT: potential effects of drugs. *Eur. J. Nucl. Med. Mol. Imaging* **35**, 424–438 (2008).
- ⁵¹ Shang, Y. et al. Displacement of Serotonin and Dopamine Transporters by Venlafaxine Extended Release Capsule at Steady State: A [123I]2β-Carbomethoxy-3β-(4-Iodophenyl)-Tropane Single Photon Emission Computed Tomography Imaging Study. *J. Clin. Psychopharmacol.* **27**, 71–75 (2007).
- ⁵² Madras, B. K. et al. Dopamine Transporter (DAT) Inhibitors Alleviate Specific Parkinsonian Deficits in Monkeys: Association with DAT Occupancy in Vivo. *J. Pharmacol. Exp. Ther.* **319**, 570–585 (2006).

-
- ⁵³ Kilbourn, M. R., Kemmerer, E. S., Desmond, T. J., Sherman, P. S. & Frey, K. A. Differential effects of scopolamine on *in vivo* binding of dopamine transporter and vesicular monoamine transporter radioligands in rat brain. *Exp. Neurol.* **188**, 387–390 (2004).
- ⁵⁴ Xiao, Z. et al. Changes of dopamine transporter function in striatum during acute morphine addiction and its abstinence in rhesus monkey. *Chin. Med. J. (Engl.)* **119**, 1802–1807 (2006).
- ⁵⁵ Collins, S. L., Gerdes, R. M., D'Addario, C. & Izenwasser, S. Kappa opioid agonists alter dopamine markers and cocaine-stimulated locomotor activity. *Behav. Pharmacol.* **12**, 237–245 (2001).
- ⁵⁶ Bergström, K. A. et al. Fentanyl decreases beta-CIT binding to the dopamine transporter. *Synap. N. Y. N* **29**, 413–415 (1998).
- ⁵⁷ Zaaier, E. R. et al. Effect of extended-release naltrexone on striatal dopamine transporter availability, depression and anhedonia in heroin-dependent patients. *Psychopharmacology (Berl.)* **232**, 2597–2607 (2015).
- ⁵⁸ Tsukada, H. et al. Ketamine alters the availability of striatal dopamine transporter as measured by [(11)C]beta-CFT and [(11)C]beta-CIT-FE in the monkey brain. *Synap. N. Y. N* **42**, 273–280 (2001).
- ⁵⁹ Harada, N., Ohba, H., Fukumoto, D., Kakiuchi, T. & Tsukada, H. Potential of [(18)F]beta-CFT-FE (2beta-carbomethoxy-3beta-(4-fluorophenyl)-8-(2-[(18)F]fluoroethyl)nortropine) as a dopamine transporter ligand: A PET study in the conscious monkey brain. *Synap. N. Y. N* **54**, 37–45 (2004).
- ⁶⁰ Schiffer, W. K., Logan, J. & Dewey, S. L. Positron Emission Tomography Studies of Potential Mechanisms Underlying Phencyclidine-Induced Alterations in Striatal Dopamine. *Neuropsychopharmacology* **28**, 2192–2198 (2003).
- ⁶¹ Schillaci, O. et al. The effect of levodopa therapy on dopamine transporter SPECT imaging with 123I-FP-CIT in patients with Parkinson's disease. *Eur. J. Nucl. Med. Mol. Imaging* **32**, 1452–1456 (2005).
- ⁶² Winogrodzka, A., Booij, J. & Wolters, E. C. Disease-related and drug-induced changes in dopamine transporter expression might undermine the reliability of imaging studies of disease progression in Parkinson's disease. *Parkinsonism Relat. Disord.* **11**, 475–484 (2005).
- ⁶³ Winogrodzka, A. et al. [123I]β-CIT SPECT is a useful method for monitoring dopaminergic degeneration in early stage Parkinson's disease. *J. Neurol. Neurosurg. Psychiatry* **74**, 294–298 (2003).
- ⁶⁴ Ahlskog, J. E. et al. The effect of dopamine agonist therapy on dopamine transporter imaging in Parkinson's disease. *Mov. Disord.* **14**, 940–946 (1999).
- ⁶⁵ Innis, R. B. et al. Effect of treatment with L-dopa/carbidopa or L-selegiline on striatal dopamine transporter SPECT imaging with [123I]β-CIT. *Mov. Disord.* **14**, 436–442 (1999).
- ⁶⁶ Fowler, J. S. et al. Evidence that L-deprenyl treatment for one week does not inhibit MAO A or the dopamine transporter in the human brain. *Life Sci.* **68**, 2759–2768 (2001).
- ⁶⁷ Taylor, J. et al. Cholinesterase inhibitor use does not significantly influence the ability of 123I-FP-CIT imaging to distinguish Alzheimer's disease from dementia with Lewy bodies. *J. Neurol. Neurosurg. Psychiatry* **78**, 1069–1071 (2007).
- ⁶⁸ Lavalaye, J. et al. [123I]FP-CIT binding in rat brain after acute and sub-chronic administration of dopaminergic medication. *Eur. J. Nucl. Med. Mol. Imaging* **27**, 346–349 (2000).
- ⁶⁹ Mateos, J. J. et al. Lower striatal dopamine transporter binding in neuroleptic-naive schizophrenic patients is not related to antipsychotic treatment but it suggests an illness trait. *Psychopharmacology (Berl.)* **191**, 805–811 (2007).
- ⁷⁰ Best, S. E. et al. Striatal dopamine transporter availability with [123I]β-CIT SPECT is unrelated to gender or menstrual cycle. *Psychopharmacology (Berl.)* **183**, 181–189 (2005).
- ⁷¹ Cilia, R., Marotta, G., Belletti, A., Siri, C. & Pezzoli, G. Reversible dopamine transporter reduction in drug-induced parkinsonism. *Mov. Disord.* **29**, 575–577 (2014).
- ⁷² Booij, J. et al. [123I]FP-CIT SPECT shows a pronounced decline of striatal dopamine transporter labelling in early and advanced Parkinson's disease. *J. Neurol. Neurosurg. Psychiatry* **62**, 133–140 (1997).
- ⁷³ Booij, J. One-Day Protocol for Imaging of the Nigrostriatal Dopaminergic Pathway in Parkinson's Disease by [123I]FP-CIT SPECT. **10**.
- ⁷⁴ Grabher, B. J. Brain Imaging Quality Assurance: How to Acquire the Best Brain Images Possible. *J. Nucl. Med. Technol.* **47**, 13–20 (2019).